

# BEST DISEASE ASSOCIATED WITH MACULAR HOLE

---

Ramin Nourinia, MD, Danial Roshandel, MD, Behzad S. Lima, MD,  
Shima Sayanjali, MD

---

**Purpose:** To report a case of Best vitelliform macular dystrophy complicated by macular hole.

**Methods:** History and clinical examination, electroretinogram, and optical coherence tomography.

**Results:** We report a case of a 20-year-old boy with progressive visual loss in his left eye. In fundus examination, there was a typical vitelliform lesion in the right eye and a macular hole in the left eye. The electroretinogram Arden ratio was  $<1.1$  in both eyes. Optical coherence tomography revealed deposition of hyperreflective material and hyporefective area between the junction of the inner segment and outer segment of the photoreceptors and the retinal pigment epithelium in the right eye, and large full-thickness macular hole with cystoid changes in the retinal layers in the left eye. There was no associated retinal detachment.

**Conclusion:** Although extremely rare, macular hole should be considered as a cause of the significant visual loss in patients with Best vitelliform macular dystrophy.

**RETINAL CASES & BRIEF REPORTS 9:7–12, 2015**

---

*From the Ophthalmic Research Center, Labbafinejad Medical Center, Shahid Beheshti University of Medical Sciences, Tehran, Iran.*

Best vitelliform macular dystrophy or Best disease was first described by Fredrich Best in 1905. Although primarily known as an autosomal dominant disease, there are reports of autosomal recessive inheritance.<sup>1</sup> Clinically, it presents initially with deposits resembling an egg yolk (vitelliform stage), but the vitelliform lesions disperse like “scrambled egg” (vitelliruptive stage) later. The lesion may progress to pseudohypopyon and finally to atrophic stages in which choroidal neovascularization may occur.<sup>2,3</sup>

Application of new generations of optical coherence tomography (OCT) increased our knowledge about the evolution of lesion in different stages of Best disease. The previtelliform lesion is characterized by a thicker layer between the retinal pigment epithelium (RPE)

and the inner segment and outer segment interface. In all progressive stages from the vitelliform to the vitelliruptive stage, the vitelliform material is seen as highly reflective lesion located between the hyporefective outer nuclear layer and the hyperreflective RPE layer. At the vitelliruptive and atrophic stages, on some parts, hyperreflective mottling on the RPE layer probably representing the areas of focal RPE hypertrophy may be seen. The atrophic stage and the fibrotic stage are characterized by thinning of all the retinal layers and diffuse loss of the inner segment and outer segment interface.<sup>3,4</sup>

Other OCT findings in patients with Best disease include cystoid changes in outer plexiform layer and rarely full-thickness macular hole with associated retinal detachment.<sup>5</sup>

In this report, we present a case with Best vitelliform macular dystrophy that presented with full-thickness macular hole and cystoid changes in outer retinal layers.

## Case Report

A 20-year-old young boy referred with metamorphopsia and progressive decrease in visual acuity of his left eye for 1 year. He had no history of ocular or systemic illness or medication. Best-corrected visual acuity was 20/20 and 20/400 in the right

---

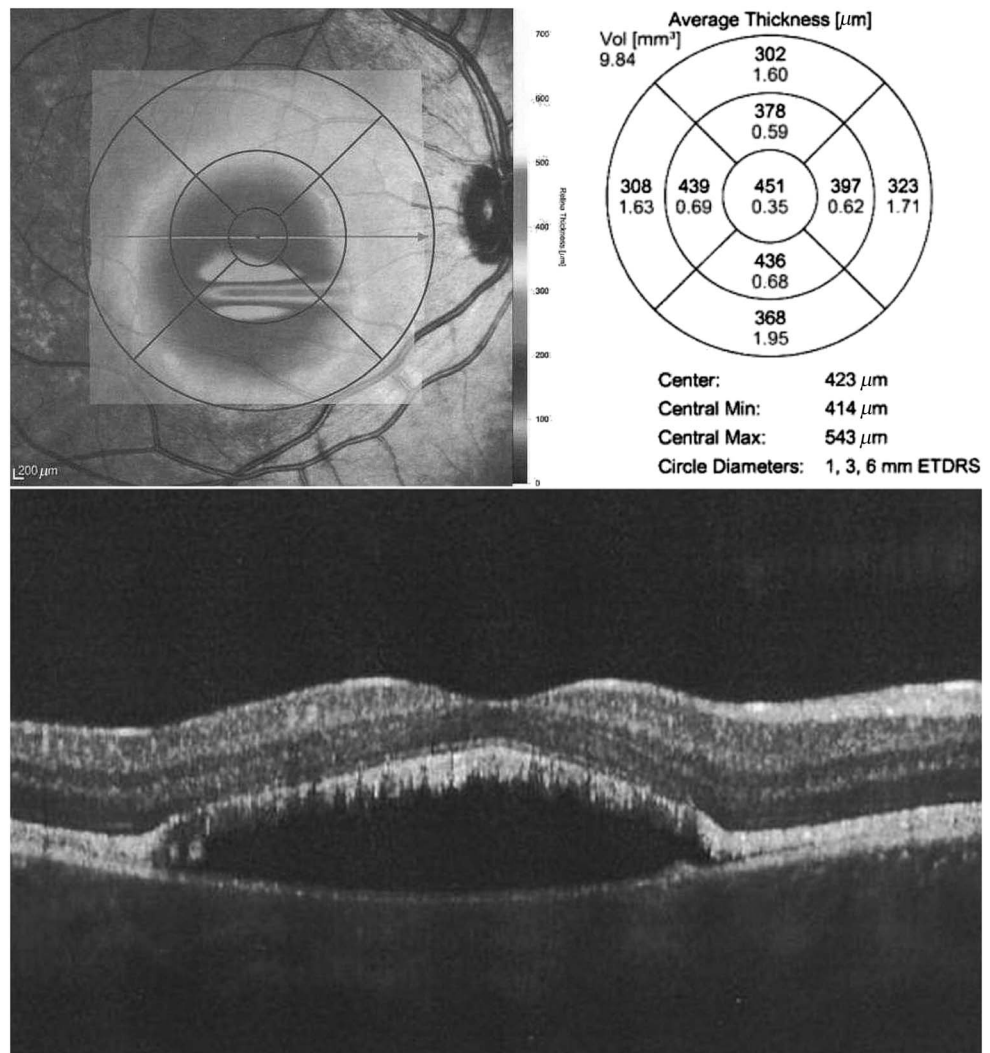
None of the authors have any financial/conflicting interests to disclose.

Reprint requests: Danial Roshandel, MD, Department of Ophthalmology, Labbafinejad Medical Center, Paidarfard Street, Boostan 9 Street, Pasdaran, Tehran 16666, Iran; e-mail: roshandel\_d@yahoo.com

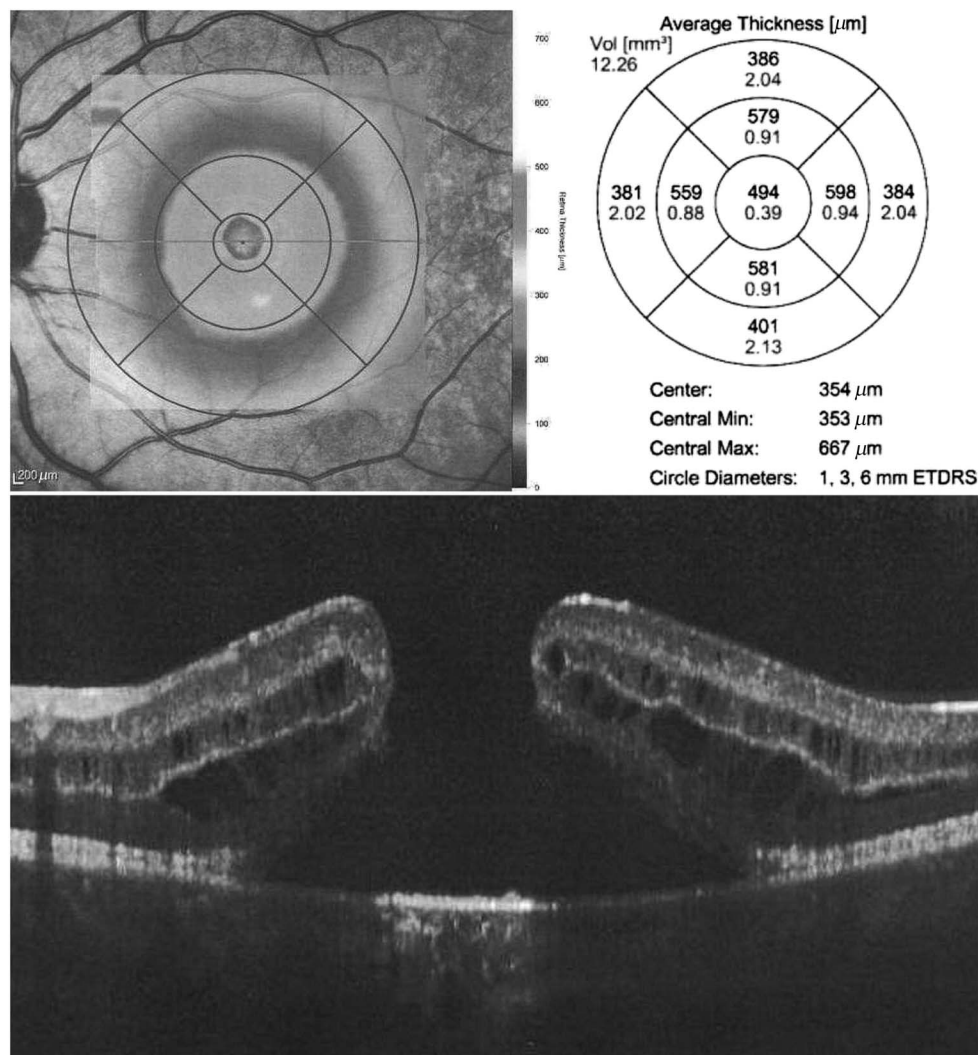
and left eyes, respectively. There was no relative afferent papillary defect. Examinations of anterior segment were unremarkable, and intraocular pressure was in the normal range in both eyes. In fundus examination, the vitreous, disk, and retinal vessels were normal in both eyes. In the right eye, an elevated large yellow round macular lesion measuring ~2 disk diameter across was found (vitelliform stage). In the left eye, a full-thickness retinal defect with elevated edges was noted. There was no clinical sign of epiretinal membrane in both eyes. Eye-tracking spectral domain OCT (Spectralis; Heidelberg Engineering, Heidelberg, Germany) was performed with the Early Treatment Diabetic Retinopathy Study protocol in central 1, 3, and 6 mm and presented in single-line horizontal scans centered on the fovea (axial resolution of 8 μm and scanning rate of 40 kHz). Optical coherence tomography revealed thickening of the neurosensory retina without cystoid changes and an accumulation of hyperreflective material beneath the photoreceptors layer with a large hyporeflective area beneath them in the right eye (Figure 1). These changes were not observed in the retina outside the fovea. In the left eye, a full-thickness macular hole was observed with thickened and rolled edges and cystoid changes in the inner and outer nuclear layers and the RPE atrophy in the macular hole bed, indicating the chronicity of the

process (Figure 2). The extrafoveal retina seemed to be normal. There was no evidence of vitreomacular traction in both eyes. Short wave fundus autofluorescence (HRA; Heidelberg Engineering) showed a hyperautofluorescent ring in both eyes (Figure 3, A and B). Fluorescein angiography (HRA; Heidelberg Engineering) revealed an area of hyperfluorescence in early phases remaining in the same size and increased intensity indicating window defect secondary to localized RPE atrophy (Figure 4, A and B). The hyperautofluorescent ring in fundus autofluorescence was consistent with the hyperfluorescent area in fluorescein angiography, which is an indicator of stressed RPEs in the edge of the atrophic area. Electrooculogram (Mon2008H; Metrovision, Pérenchies, France) was performed for both eyes according to the standard protocols, and the Arden ratio was calculated, which was characteristically low in both eyes (Figure 5).

An examination of the family members revealed bilateral macular lesion with OCT findings typical of best vitelliform macular dystrophy (except for macular hole which was not observed, Figure 6, A and B) in his 23-year-old sister. There was no evidence of macular lesion in fundus examination and OCT and no abnormality in electroretinogram in his parents and other siblings.



**Fig. 1.** Spectral domain OCT of the right eye showing hyperreflective material between the inner segment and outer segment junction and the RPE, hyporeflective space, and filament-like bridges between the photoreceptor outer segments and the RPE.



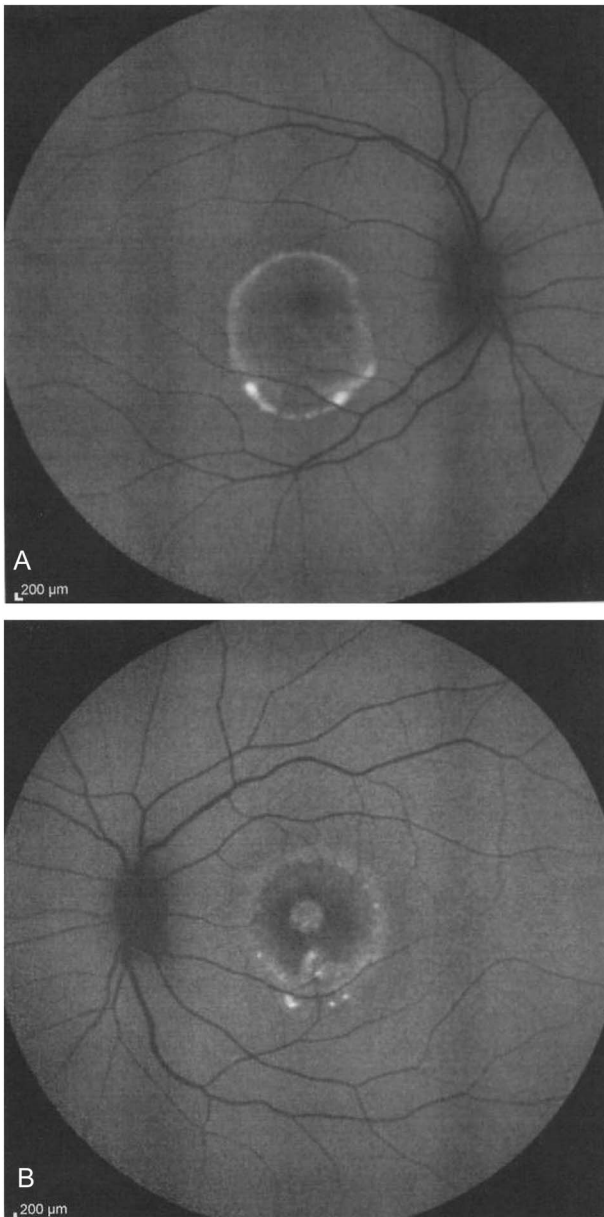
**Fig. 2.** Spectral domain OCT of the left eye. Large full-thickness macular hole (the diameter was 280  $\mu\text{m}$  in the apex and 1100  $\mu\text{m}$  in the macular hole bed) with elevated rolled edges and cystoid changes indicating the chronicity of the macular hole.

### Discussion

Best disease, is a rare, albeit one of the most common, hereditary juvenile onset macular dystrophies with autosomal dominant inheritance in a majority of cases. Clinically, it can be manifested in sequential stages, although the chronology might differ in some cases.<sup>2</sup> An examination of the family members revealed typical vitelliform lesion in both eyes and typical electroretinogram finding in one of his siblings (his sister), while other siblings and his parents were normal in funduscopic examination and electroretinogram. Because of the lack of genetic confirmation, we considered presumed autosomal recessive pattern for this case, which is rare in Best disease.<sup>1</sup>

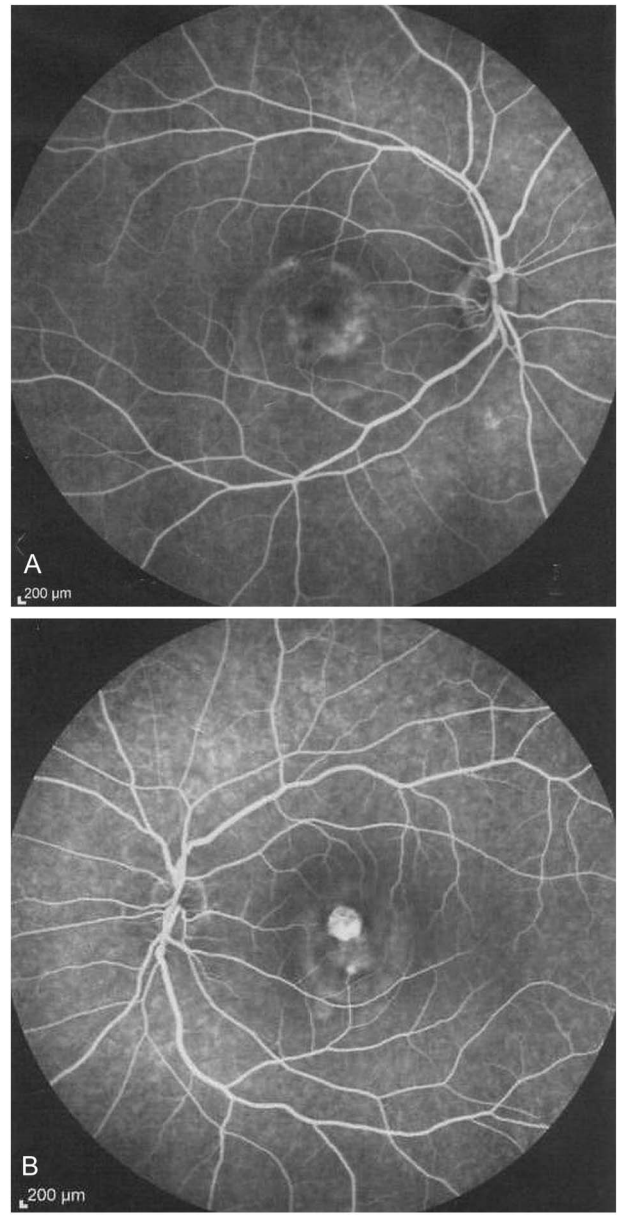
A typical OCT finding in eyes with Best disease includes deposition of hyperreflective material in a deep retinal band so-called outer retina–RPE–choroid complex in the early stages.<sup>6</sup> Other findings include

intraretinal fluid, swelling, and thickening of the outer retina–RPE–choroid complex. Elevation of the retina with increased subretinal reflectiveness is noted in the vitelliform stage.<sup>7</sup> Findings in the pseudohypopyon stage include subretinal hyperreflectiveness corresponding to the material deposit and hyporefectiveness corresponding to the subretinal liquid.<sup>7</sup> Such findings were observed in the right eye of our patient (Figure 1). Subtle changes may also occur in the previtelliform stage including highly reflective layer between the RPE and the inner segment and outer segment junction.<sup>8</sup> Large deposits extending up to the outer plexiform layer, thickening and elongation of photoreceptor outer segments, small filament-like bridges between the photoreceptor outer segment layer and the RPE, and the absence of Verhoeff membrane, the interface between cone photoreceptors and the RPE, were noted by Gerth et al.<sup>9</sup> In their study, the inner retinal layers were not affected.<sup>9</sup>



**Fig. 3.** Fundus autofluorescence shows hyperautofluorescent ring at the macula in both eyes (A and B) and at the fovea of the left eye (B).

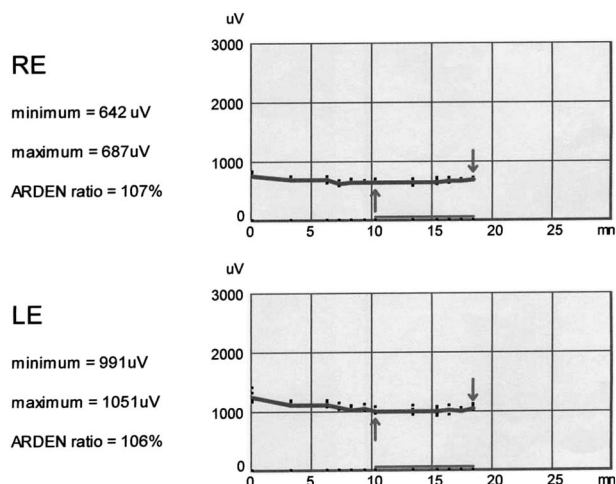
In our case, OCT of the right eye revealed increased retinal thickness with typical fluid accumulation beside hyperreflective deposits between the inner segment and outer segment junction and the RPE, which was compatible with the vitelliform stage. There was also thickening and elongation of the photoreceptor outer segments and small filament-like bridges between the photoreceptor outer segment layer and the RPE as it was seen by Greth et al.<sup>9</sup> In the left eye, OCT findings include a large full-thickness macular hole with rolled and elevated edges and cystoid changes in the outer and inner nuclear layers. Beyond the area of macular



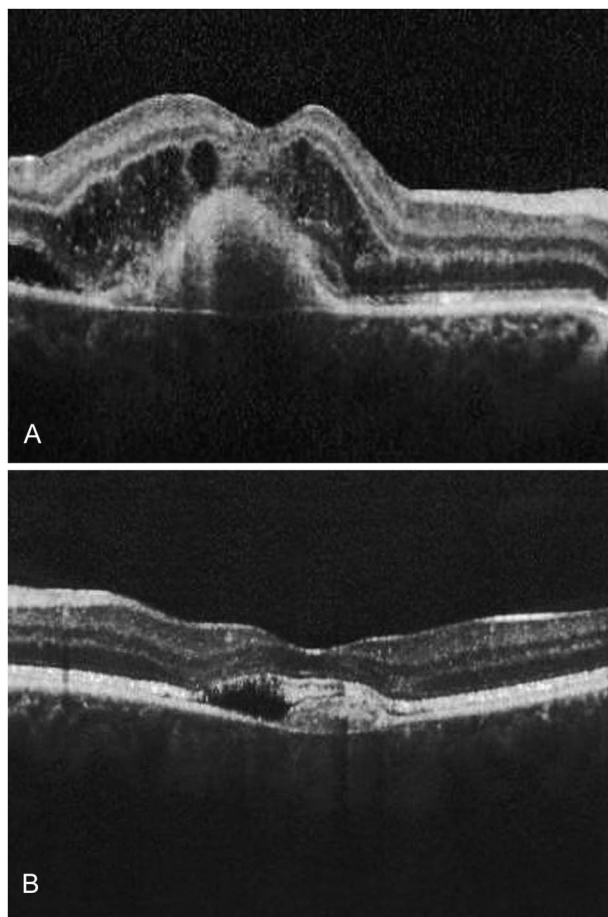
**Fig. 4.** Fluorescein angiography. There is hyperfluorescence compatible with window defect because of the RPE atrophy in the right eye (A) and macular hole in the left eye (B).

hole, there was a hyporeflective space beneath the retina including hyperreflective deposits between the outer retina and the RPE. There was severe thickening of the retina with cystoid changes.

Interestingly, in both the patient and his sister, OCT findings were different between the two eyes. The left eye of the patient (Figure 2) and the right eye of his sister (Figure 6A) that had poorer visual acuity, showed severe macular thickening with large cystoid spaces and non-detectable foveal contour, and albeit macular hole in the patient. In the fellow eye, (Figures 1 and 6B) accumulation of the subretinal fluid and hyperreflective material



**Fig. 5.** Electrooculogram shows a significant decrease of Arden ratio in both eyes, which is typical of Best disease.



**Fig. 6.** Spectral domain OCT of the patient's sister showing subretinal hyperreflective material in both eyes typical of the vitelliform stage of Best vitelliform macular dystrophy (A: right eye, B: left eye). There is significant macular thickening and distortion and cystoid changes in the outer plexiform layer in the right eye (A). Visual acuity was 20/100 and 20/30 in the right and the left eyes, respectively.

was seen beside photoreceptor outer segment elongation, preservation of the foveal contour, and the otherwise normal neurosensory retina without cystoid spaces.

There are few reports of Best disease complicated with macular hole with associated retinal detachment.<sup>5,10</sup> Macular hole without associated retinal detachment as observed in our case is extremely rare. To the best of our knowledge, there is only one report of this complication in the literature.<sup>11</sup> It is unclear about how a vitelliform lesion evolves to a macular hole.

Goldberg and Freund<sup>12</sup> studied the evolution of macular hole in a patient with an adult onset acquired vitelliform lesion by using high-resolution eye-tracking spectral domain OCT and suggested that the progressive foveal outer retinal atrophy, rather than vitreofoveal traction, is responsible for this complication. However, the mechanism might be different in hereditary best vitelliform macular dystrophy cases.

Our case is unusual, firstly, because of its autosomal recessive inheritance, and secondly, by evolution of full-thickness macular hole in the absence of retinal detachment.

In conclusion, OCT is a useful tool for diagnosis of different features of Best disease especially in cases with significant decrease in vision. Macular hole formation with or without retinal detachment is a rare but important complication of Best disease that may develop as a consequence of severe cystoid change and result in significant worsening of visual acuity.

**Key words:** Best vitelliform macular dystrophy, optical coherence tomography, macular hole.

## References

1. Bitner H, Mizrahi-Meissonnier L, Griefner G, et al. A homozygous frameshift mutation in BEST1 causes the classical form of Best disease in an autosomal recessive mode. *Invest Ophthalmol Vis Sci* 2011;52:5332–5338.
2. Gass JD. Heredodystrophic disorders affecting the pigment epithelium and retina. In: *Stereoscopic Atlas of Macular Diseases Diagnosis and Treatment*. Vol 1. 4th ed. Gass JD (Ed.). St Louis, MO: Mosby; 1997:304–325.
3. Boon CJ, Klevering BJ, Leroy BP, et al. The spectrum of ocular phenotypes caused by mutations in the BEST1 gene. *Prog Retin Eye Res* 2009;28:187–205.
4. Querques G, Regenbogen M, Quijano C, et al. High-definition optical coherence tomography features in vitelliform macular dystrophy. *Am J Ophthalmol* 2008;146:501–507.
5. Glacet-Bernard A, Coscas G. Full-thickness macular hole and retinal detachment complicating Best's disease. *Eur J Ophthalmol* 1993;3:53–54.
6. Pianta MJ, Aleman TS, Cideciyan AV, et al. In vivo micro-pathology of Best macular dystrophy with optical coherence tomography. *Exp Eye Res* 2003;76:203–211.

7. Schatz P, Klar J, Andréasson S, et al. Variant phenotype of Best vitelliform macular dystrophy associated with compound heterozygous mutations in VMD2. *Ophthalmic Genet* 2006;27:51–56.
8. Ferrara DC, Costa RA, Tsang S, et al. Multimodal fundus imaging in Best vitelliform macular dystrophy. *Graefes Arch Clin Exp Ophthalmol* 2010;248:1377–1386.
9. Gerth C, Zawadzki RJ, Werner JS, Héon E. Detailed analysis of retinal function and morphology in a patient with autosomal recessive bestrophinopathy (ARB). *Doc Ophthalmol* 2009; 118:239–246.
10. Schachat AP, de la Cruz Z, Green WR, Patz A. Macular hole and retinal detachment in Best's disease. *Retina* 1985;5:22–25.
11. Mehta M, Katsumi O, Tetsuka S, et al. Best's macular dystrophy with a macular hole. *Acta Ophthalmol (Copenh)* 1991;69:131–134.
12. Goldberg N, Freund KB. Progression of an acquired vitelliform lesion to a full-thickness macular hole documented by eye-tracked spectral-domain optical coherence tomography. *Arch Ophthalmol* 2012;130:1221–1223.