

## Refixation strategies in four patients with macular disorders

Florence Duret<sup>1</sup>  
Cathy Buquet<sup>2</sup>  
Jacques Charlier<sup>2</sup>  
Christophe Mermoud<sup>1</sup>  
Paolo Viviani<sup>3,4</sup>  
Avinoam B. Safran<sup>1</sup>

<sup>1</sup>Neuro-ophthalmology Unit, Ophthalmology Clinic, Geneva University Hospitals, Geneva, and <sup>3</sup>Department of Psychobiology, Faculty of Psychology, Geneva University, Geneva, Switzerland; <sup>2</sup>INSERM U279, Lille, France  
<sup>4</sup>Faculty of Psychology, HSR Vita-Salute University, Milan, Italy

**Abstract** *Purpose:* This study was undertaken to identify visual search strategies performed during refixation tasks in four patients with central scotomas. *Methods:* Eye movements of tested patients were recorded while they alternately fixate a central spot and recognized letters successively projected in various locations. *Results:* Five oculomotor behavior patterns could be identified: (1) a 'foveation-defoveation' strategy, directing the anatomic fovea, then the PRL, close to the target image; (2) a 'direct refixation' strategy, orienting the preferred retinal locus (PRL) straight onto the target image; (3) a 'staircase' strategy, bringing the PRL by means of short successive saccades progressively closer to the target image; (4) a 'withdrawal' strategy, in which the scotoma was directed far away from the target image and then the PRL was brought onto it; and (5) a 'no-movement' behavior, in which the subject attempted to decipher the letter from his initial gaze position. *Conclusion:* Findings suggest that the visuomotor behaviors in the four studied patients were related to a variety of factors, including the location of the target image relative to the scotoma, the spatial characteristics of the defect, and the duration of the disease.

**Key words** Eye movements; macular disease; preferred retinal locus (PRL); visual field; visual search

**Introduction** Clinical observations of patients with central scotomas due to macular disorders have shown that, with time and practice, most affected subjects employ at least one eccentric retinal area, the 'preferred retinal locus' (PRL). The PRL is required to accomplish tasks involving a fixation, such as inspecting visual details and reading.<sup>1-6</sup> It is usually located on the edge of the lesion, in the inferior part of the visual field.<sup>2,5-11</sup>

*Correspondence and reprint requests to:*

Avinoam B. Safran, MD  
Ophthalmology Clinic  
Department of Clinical Neuroscience  
Geneva University Hospitals  
22, rue Alcide Jentzer  
1211 Geneva 14  
Switzerland  
Fax: +41 22 346 84 05

*Acknowledgments:* This investigation was supported by grants #3200-040780.94 and #3200-0409594.96 from the Swiss National Fund for Scientific Research, by the Association pour le Bien des Aveugles, Geneva, Switzerland, by the Sandoz Research Foundation, and by the de Reuter Foundation.

Most authors agree that the PRL is stable, usually being located in a single place for a given subject and a given task.<sup>2,12</sup>

Few studies have been performed on the oculomotor behavior of patients with macular disorders. White and Bedell<sup>5</sup> recorded eye movements performed by 21 subjects with central scotoma, using a frame-by-frame playback video. Fifteen patients were reported to show normal eye movements, imaging the target at the PRL, while two others performed more than three movements to direct the target's image near the PRL. Two more patients did not reliably make eye movements and the last two patients showed oculomotor behaviors that could not be analyzed. More recently, Schuchard and Fletcher<sup>13</sup> showed that during visual search, the latency of the saccades is increased and, on average, more saccades of shorter size occur in affected subjects than in normally sighted individuals.

The aim of our study was to develop a procedure allowing the analysis of oculomotor behavior patterns in patients with central scotomas. This method was used for the identification of oculomotor behavior patterns in four affected patients performing simple tasks of refixation. In this series of patients, five oculomotor behavior patterns were recognized.

**Methods and patients** We investigated four patients with central scotomas due to macular disorders. For this study, we selected subjects showing relative fixation stability in a simple fixation task. This was achieved by asking eleven affected patients to look at the tip of a vertical stick. We took a series of ten photographs of each tested patient using a fundus camera. Of these patients, four individuals consistently used one PRL that was circumscribed in a 2x2 degree area, i.e., showed relative stability according to the criteria proposed by Timberlake et al.<sup>3</sup> and Whittaker et al.<sup>14</sup> Their clinical characteristics are displayed in Table 1.

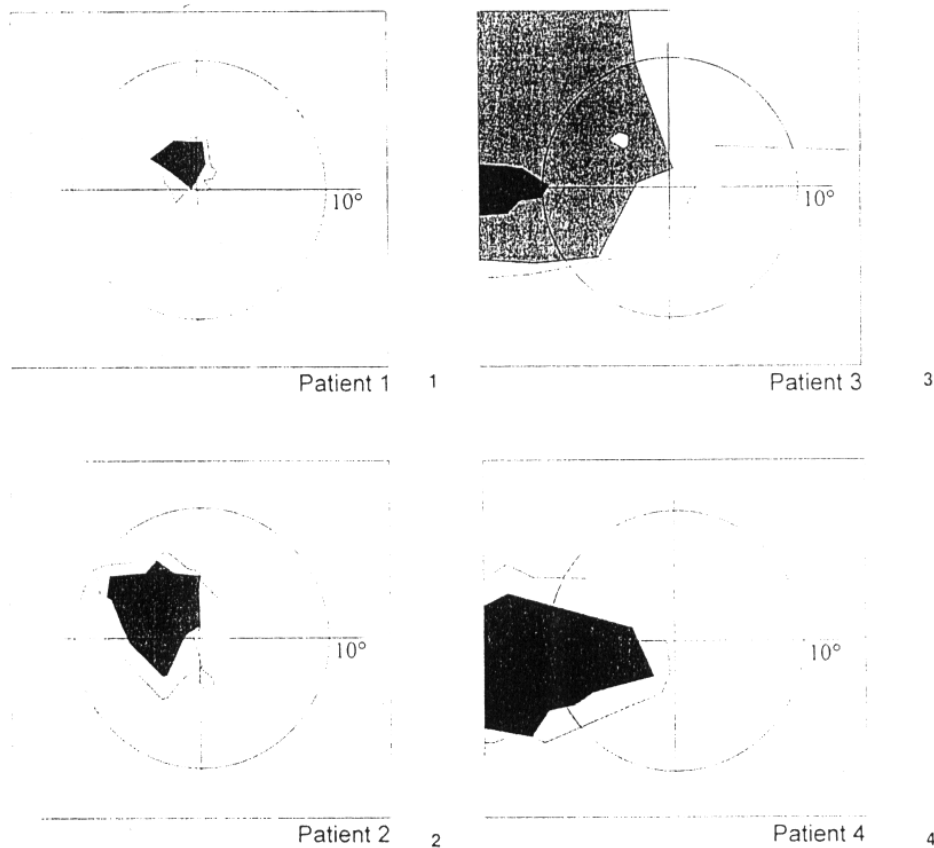
We evaluated visual field defects using a tangent screen at a distance of one meter. The first stimulus used was 2 mm in diameter, and the defects thus delineated were referred to as 'moderate scotomas'. Stimuli 10 mm in diameter and, when necessary, 14 mm in diameter were then used to delineate so-called 'deep scotomas'. In Patients 1, 2, and 4, the PRL was located at the border of the visual field defect. In Patient 3, the PRL was located within the altered area of the visual field (Fig. 1). Then, we verified that the localization of the scotoma relative to the fixation locus observed using the fundus camera was in accordance with the localization of the scotoma relative to the fixation locus observed using the tangent screen examination.

We then recorded eye movements during refixation tasks. For testing refixation strategies, the patients were asked to fixate a 30 min of arc white

TABLE 1. Clinical characteristics of the patients.

Patient	Age (yr)	Uni- or bilateral lesion	Tested eye	Visual acuity	Diagnosis	Duration of the disorder (yr)
1	43	Unilateral	OD	0.16	MH	¼
2	63	Bilateral	OS	0.5	AMD	2
3	81	Bilateral	OS	0.12	AMD	5
4	84	Bilateral	OS	0.10	AMD	4

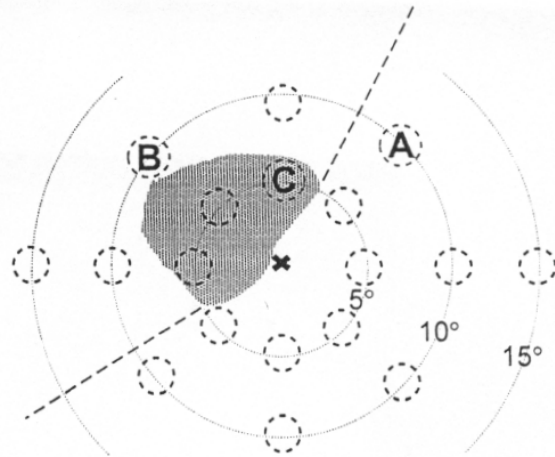
AMD, age-related macular degeneration; MH, macular hole.



spot, projected using a slide onto the center of a screen. After five seconds, the slide was replaced by another one showing an eccentric letter  $0.8^\circ$  in height. The patient was made aware of slide replacement by the slight noise produced by the mechanical part of the projector. The patient then had 10 seconds to attempt to recognize the projected letter. This procedure was performed 18 times in succession. Each time, a different letter was randomly projected in one of the following positions:  $5^\circ$ ,  $10^\circ$ , and  $15^\circ$  to the left and right of the vertical axis on the horizontal meridian;  $5^\circ$  and  $10^\circ$  above and below the horizontal meridian on the vertical axis; and  $5^\circ$  and  $10^\circ$  eccentrically on the  $45^\circ$ - $225^\circ$  and the  $135^\circ$ - $315^\circ$  oblique meridians (Fig. 2). The test was conducted twice in succession. Eye movements were recorded with a bright pupil, infra-red technique,<sup>15-18</sup> using an instrument made by Metrovision (Lille, France).<sup>19</sup> This technique is based on the evaluation of the relative positions of the first corneal reflection and the center of the pupil. The measurements were performed 30 times per second. Precision was within a range of 20 min of arc. Limits of gaze eccentricity were  $\pm 30^\circ$ . To analyze oculomotor behavior patterns in relation to spatial characteristics of the visual field defect, we used software developed in our laboratory.<sup>20</sup> It allowed a step-by-step two-dimensional analysis of eye-movement recordings and enabled us to superimpose continuously on the display the area of the scotoma relative to the fixation locus. According to their position with respect to the scotoma and the PRL, target letters were considered

Fig. 1. Visual field in the tested eye of patients, evaluated using a tangent screen. Light gray areas represent defects which were delineated using a 0.2 cm stimulus, medium gray areas show defects delineated with a 1 cm stimulus, and dark gray areas show defects delineated with a 1.4 cm stimulus. Circles are 20 degrees in diameter. In Patient 3, the scotoma extended beyond the limits shown on the left, superior, and upper right borders. For practical reasons, linear limits have been arbitrarily drawn in the corresponding sectors. Similarly, in Patient 4, the scotoma extended beyond the left border of the visual field defect shown. The PRL are centered on the point of x/y coordinates (0;0). Location of the original fixation point could not be indicated precisely, but, considering the condition, probably lies close to the center of the scotoma.

Fig. 2. Locations of the successively projected letters, with a schematic representation of the position of the scotoma (light gray area), and of the preferred retinal locus (x). Dotted lines delineate the area including the target position (A) opposite the scotoma from that including the target location within (C) or beyond (B) the scotoma, with respect to the position of the PRL.



to be located 'opposite' the scotoma, 'beyond' the scotoma, or 'within' the scotoma.

Analysis was limited to those traces which met the following criteria: (1) there were no repeated interruptions by blinks, making the analysis unreliable; (2) the oculomotor pattern could be clearly recognized; and (3) the identified pattern was observed more than five times in our recordings (in other words, the strategy was used with some consistency in our patients). Our research conformed to the Declaration of Helsinki. All patients gave their informed consent to the testing procedures and approval was obtained from the appropriate human experimentation committee.

**Results** Five oculomotor behavior patterns were recognized (Fig. 3).

1 A 'foveation-defoveation' strategy. A first saccade brought the anatomic fovea close to the location of the target letter onto an area of moderate scotoma. Then, an upward corrective movement of about  $2^\circ$  in amplitude directed the PRL onto the image of the target. An example of such a recording is shown in Figure 4.

2 A 'direct refixation' strategy. This consisted of a saccade performed onto the target letter, followed by a second corrective eye movement, completing the refixation, when the saccade was hypometric (up to  $3^\circ$ ) or hypermetric (up to  $2^\circ$ ). An example of such a recording is shown in Figure 5.

3 A 'staircase' strategy. The PRL was progressively brought closer to the target image by a series of short successive saccades. The saccades were four to six in number and less than  $5^\circ$  in amplitude. An example of such a recording is shown in Figure 6.

4 A 'withdrawal' strategy. Using one or two saccades,  $10^\circ$ - $20^\circ$  in amplitude, the scotoma was projected farther away from the image of the target letter. Then, the initial PRL was brought closer to the image of the letter using a sequence of saccades. An example of such a recording is shown in Figure 7.

5 A 'no-movement' behavior. The subject tried to decipher the target letter from his initial gaze position. This behavior occurred at the beginning of the testing procedure.

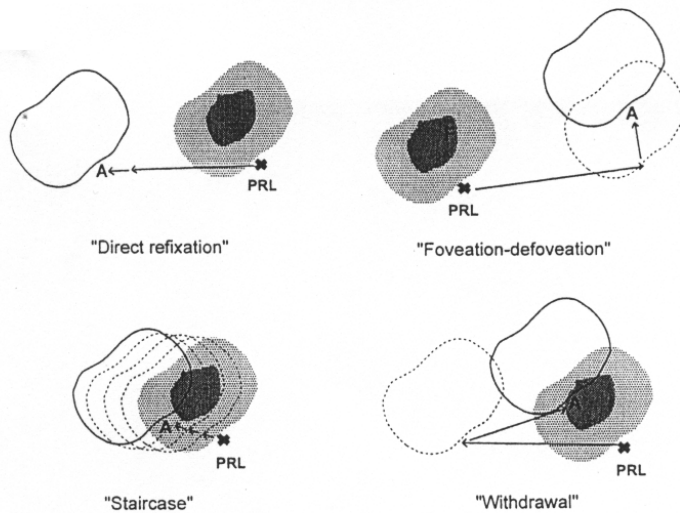
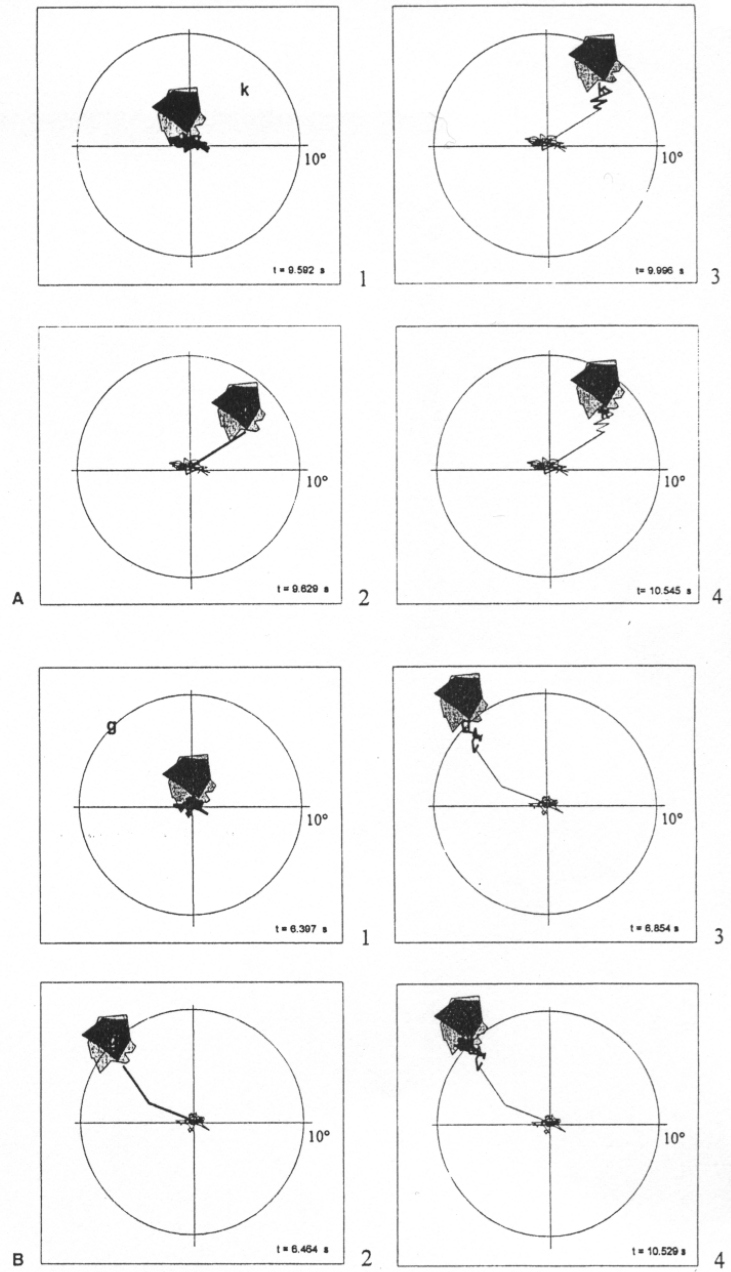


Fig. 3. Schematic representation of the identified refixation strategies. The 'direct refixation' strategy orients the PRL straight onto the target image. In the strategy shown here, the first saccade is hypometric. The 'foveation-defoveation' strategy directs the anatomic fovea, then the PRL, close to the target image. The 'staircase' strategy brings the PRL by means of short successive saccades progressively closer to the target image. The 'withdrawal' strategy directs the scotoma far away from the target image and then brings PRL onto it. The 'no-movement' behavior, in which the subject attempts to decipher the letter from his initial gaze position is not shown. Light gray area, scotoma location and variations in relative depth of the defect; PRL, preferred retinal locus; F, estimated initial position of the anatomic fovea; dotted lines, intermediate scotoma positions; continuous lines, final scotoma positions; A, locations of the projected letters.

Table 2 provides an overview of the occurrence rate of these oculomotor patterns in our patients. In Patient 1, who presented a unilateral defect, the 'foveation-defoveation' strategy was frequently used. In Patients 1 and 2, owing to the fact that they had a scotoma less than 10° in diameter, the target letter was frequently projected opposite or beyond the scotoma. In these conditions, therefore, both patients used a 'direct refixation' strategy. Hypermetric saccades occurred only when the target was projected onto the side of the scotoma opposite the PRL; hypometric refixation occurred when the target was projected beyond the scotoma. In Patients 3 and 4, owing to the fact that the scotoma was more than 10° in diameter, the target letter was frequently projected onto an altered retinal area. When the target letter was in a moderately altered area, as mainly occurred in Patient 3, the 'staircase' strategy was employed. When the target letter was projected onto an area of deep scotoma, as occurred commonly in Patient 4, the 'withdrawal' strategy was employed. In addition, at the beginning of the testing procedure, both patients with a large scotoma used a 'no-movement' behavior when the target letter was projected onto an area of moderate scotoma and when it was opposite the scotoma.

**Discussion** In our four patients, we identified five types of oculomotor behavior patterns that were used with some consistency. With the 'foveation-defoveation' strategy, the anatomic fovea was directed close to the image of the target letter, then the PRL was brought onto the image of the letter. With the 'direct refixation' strategy, the PRL was directly oriented onto the image of the letter. With the 'staircase' strategy, the PRL was brought closer to the target image by a series of short successive saccades. With the 'withdrawal' strategy, the scotoma was first directed far away from the target image, then the PRL was brought onto the projected letter. Finally, with the 'no-movement' behavior, patients attempted to decipher the target letter while the initial gaze position was maintained.

Fig. 4. Examples of the 'foveation-defoveation' strategy performed by Patient 1. (A) A 2-D representation of the strategy. 1. Initial fixation pattern and position of the target letter. 2. A first saccade directs the target image close to the anatomic fovea. 3. A second corrective movement directs the target image closer to the PRL. 4. Final pattern of fixation with the letter being projected onto the PRL. In the representation of the trajectory followed by the eye, the last connecting lines are thicker. The time shown in the lower right-hand corner is the time elapsed since the beginning of the fixation. (B) Another 2-D representation of the strategy.



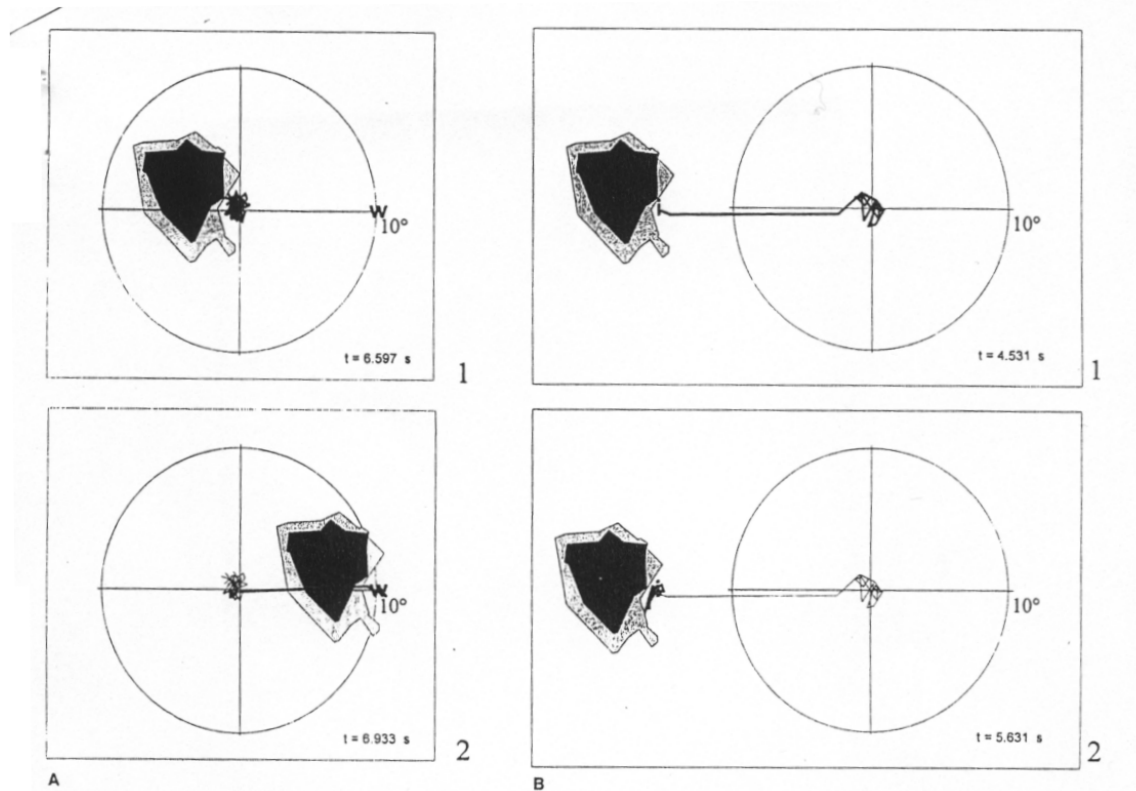


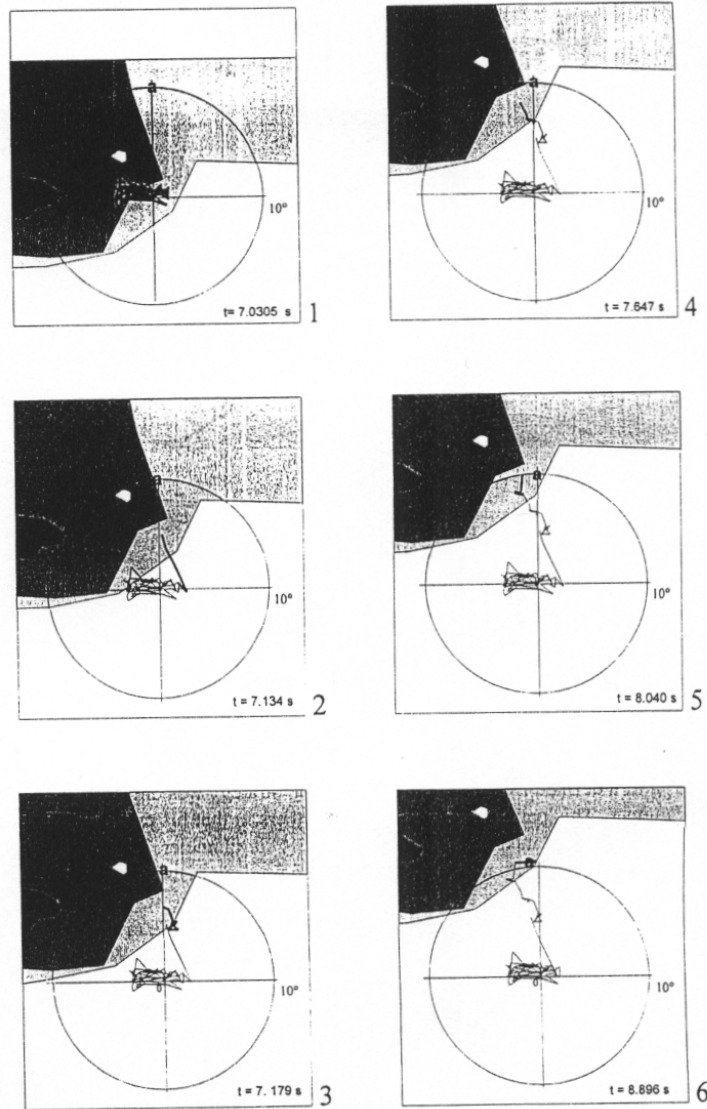
Fig. 5. Examples of the 'direct refixation' strategy performed by Patient 2. (A) A 2-D representation of the strategy. 1. Initial fixation pattern and position of the target letter. 2. Refixation saccade and final pattern of fixation, the letter being projected onto the PRL. In the representation of the trajectory followed by the eye, the last connecting lines are thicker. The time shown in the lower right-hand corner is the time elapsed since the beginning of the fixation. (B) Another 2-D representation of the strategy.

The pattern defined as 'foveation-defoveation' strategy was only observed in Patient 1. This patient differed from the others in that his retinal defect was unilateral and the scotoma was less than  $5^\circ$  in diameter. Thus, in this patient, the tested eye had apparently not been used for visual search since becoming affected. As a result, these recordings show the way a patient with a small central scotoma adapts to his condition with little or no previous training. In a study involving patients with central scotomas, White and Bedell<sup>5</sup> noted that, at least initially, eye movements brought the target's image to the affected fovea and then the motor reference shifted progressively to a nonfoveal locus. Their clinical observation was corroborated by the experimental findings of Heinen and Skavenski,<sup>21</sup> who reported that a monkey with bilateral lesions of the macula had a tendency to bring the lesioned fovea to the target and then to use a second saccade to fixate with the PRL. As a result, the 'foveation-defoveation' strategy observed in our subject can be interpreted as a nonsuppressed oculomotor behavior, using a normal foveation reflex for refixation.

The 'direct refixation' strategy was similar to the refixation patterns performed by normal subjects,<sup>22</sup> except that the fovea is somehow replaced by the PRL, which acts as a 'pseudo-fovea'. It has been shown that in normal subjects, the percentage of undershooting saccades increased as the saccade was aimed at more distant targets.<sup>22,23</sup> Similarly, in our studied patients with a central scotoma, saccades were often hypometric when the letters



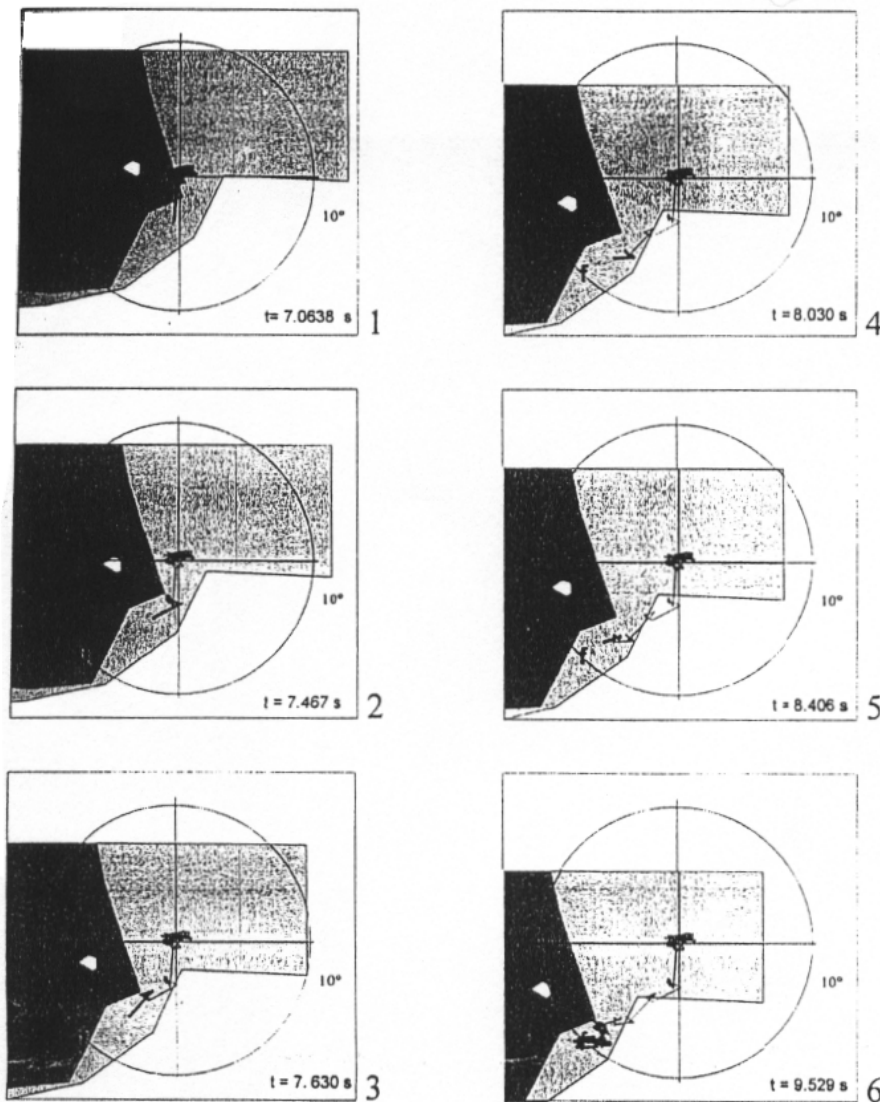
Fig. 6. Examples of the 'staircase' strategy performed by Patient 3. (A) A 2-D representation of the strategy. 1. Initial fixation pattern and position of the target letter. 2-5. The initial PRL was then brought closer to the image of the letter using a sequence of saccades. 6. Final pattern of fixation with the letter being projected onto the PRL. In the representation of the trajectory followed by the eye, the last connecting lines are thicker. The time shown in the lower right-hand corner is the time elapsed since the beginning of the fixation. (B) Another 2-D representation of the strategy.



were projected beyond the scotoma relative to the PRL (i.e., when larger saccades were required) and hypermetric when the letters were projected opposite the scotoma (i.e., when smaller saccades were required). The 'staircase' and the 'withdrawal' strategies shared similarities with that reported by Meienberg et al.<sup>24</sup> in a patient with hemianopsia, when gaze was directed toward the affected part of the visual field. These authors noted that, after training, one patient shifted from a 'staircase' strategy to a strategy employing one large saccade calculated to overshoot the target. In pa-



Fig. 6b.

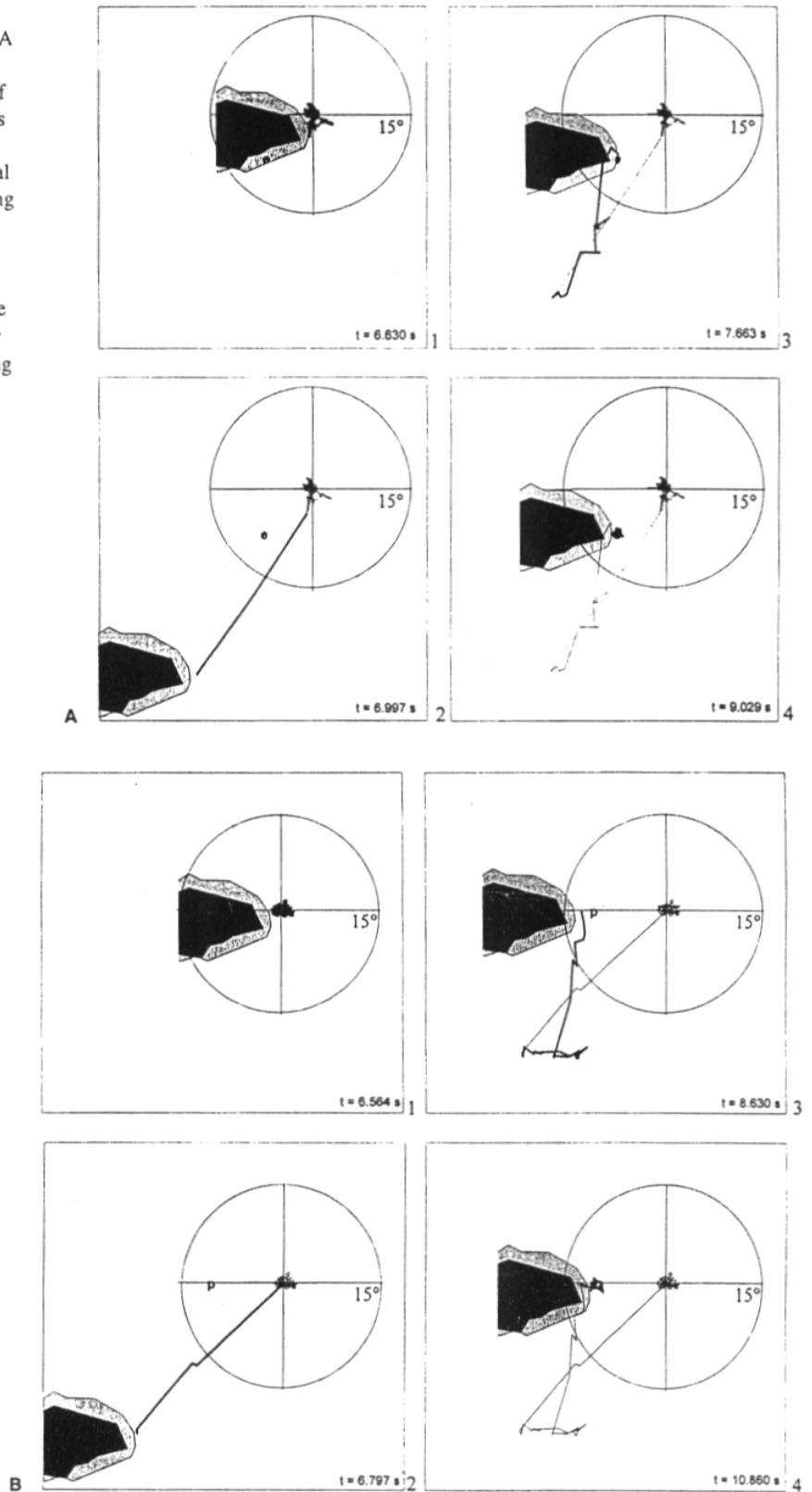


tients with hemianopsia, Zangemeister and Oeschner<sup>25</sup> showed that patients first used a low-level adaptation strategy and then were able to improve their search performance. It is conceivable that, in our patients with large macular lesions, a withdrawal strategy may be beneficial in first localizing the target using a part of the visual field that is more peripheral than the usual PRL in order to eventually project its image more accurately onto the PRL. This suggests that in a single task, several retinal areas showing different functions may be used in combination, e.g., one to localize the target and the other one to recognize it. Thus, the 'withdrawal' strategy could reflect a more adapted behavior than the staircase strategy.

Our fifth strategy, 'no-movement' behavior, was used at the beginning of the testing procedure by both patients with large scotomas and a very eccentric PRL. This suggests that, when the defect is extensive, performing adequate refixation could be perceived initially as a formidable task, and that refixation strategies were not used until the patient had become more confident with the test conditions.

Developing adapted refixation strategies involves a variety of parameters. Some have been discussed above, e.g., the position, size, and depth of the

Fig. 7. Examples of the 'withdrawal' strategy performed by Patient 4. (A) A 2-D representation of the strategy. 1. Initial fixation pattern and position of the target letter. 2. The subject directs the scotoma from the target letter. 3. Sequence of several saccades. 4. Final pattern of fixation with the letter being projected onto the PRL. In the representation of the trajectory followed by the eye, the last connecting lines are thicker. The time shown in the lower right-hand corner is the time elapsed since the beginning of the fixation. (B) Another 2-D representation of the strategy.



Patient	Target location relative to the PRL	'Direct strategy'			'Foveation-defoveation strategy'	'Staircase strategy'	'Withdrawal strategy'	'No-movement strategy'	Total
		'Hypometric saccades'	'Normometric saccades'	'Hypermetric saccades'					
1	Opposite the scotoma		3	5	6				14
	Beyond the scotoma	4	2		8				14
2	Opposite the scotoma		3	1					4
	Beyond the scotoma	3	1				1		5
	Within a moderate scotoma						1		1
3	Opposite the scotoma	1				1		5	7
	Within a moderate scotoma		1			5		1	7
4	Opposite the scotoma		1				1	3	5
	Within a moderate scotoma						3	6	9
	Within a deep scotoma						6		6
	Total	8	11	6	14	6	12	15	72

scotoma and the unilateral or bilateral nature of the condition. Additional factors should also be taken into account in further studies.

Our study was conducted on a limited number of individuals with macular disorders with the aim of performing a detailed study of their oculomotor behavior. Further studies, however, need to be undertaken to evaluate the occurrence rate of the strategies described to eventually identify additional oculomotor patterns and to determine whether the pathophysiological hypotheses presented here are corroborated by observations from larger series of patients.

TABLE 2. Oculomotor behavior patterns shown during refixation tasks. The numbers of refixation strategies indicate the number of traces showing the corresponding eye movements. Patients 1 and 2 showed scotomas that were less than 10° in diameter, whereas Patients 3 and 4 presented defective, central areas that were more than 10° in diameter.

## References

- Acosta F, Lashkari K, Reynaud X, Jalkh A, Van de Velde, FN. Characterization of functional changes in macular holes and cysts. *Ophthalmology* 1991;98:1820-1823.
- Von Noorden GK, Mackensen G. Phenomenology of eccentric fixation. *Am J Ophthalmol* 1962;53:642-649.
- Timberlake GT, Mainster MA, Peli E, Augliere RA, Essock EA, Arend LE. Reading with a macular scotoma. I. Retinal locations of scotoma and fixation area. *Invest Ophthalmol Visual Sci* 1986;27:1137-1147.
- Trauzettel-Klosinski S, Teschner C, Tornow R-P, Zrenner E. Reading strategies in normal subjects and in patients with macular scotoma assessed by two new methods of registration. *Neuro-ophthalmology* 1994;14:15-30.
- White JM, Bedell HE. The oculomotor reference in humans with bilateral macular disease. *Invest Ophthalmol Visual Sci* 1990;31:1149-1161.
- Guez J-E, Le Gargasson J-F,

- Rigaudière F, O'Regan K. Is there a systematic location for the pseudo-fovea in patients with central scotomas? *Vision Res* 1993;33:1271-1279.
- 7 Virtanen P, Laatikainen L. Low-vision aids in age-related macular degeneration. *Curr Opin Ophthalmol* 1993;4:33-35.
  - 8 Timberlake GT, Peli E, Essock EA, Augliere RA. Reading with a macular scotoma. II. Retinal locus for scanning text. *Invest Ophthalmol Visual Sci* 1987;28:1268-1274.
  - 9 Peyman GA, Koziol J. Age-related macular degeneration and its management. *J Cataract Refract Surg* 1988;4:421-490.
  - 10 Whittaker SG, Cummings RW, Swiesson LE. Saccade control without fovea. *Vision Res* 1991;31:2209-2218.
  - 11 McMahon TT, Hansen M, Viana M. Fixation characteristics in macular disease. Relationship between saccadic frequencies, sequencing, and reading rate. *Invest Ophthalmol Visual Sci* 1991;32:567-574.
  - 12 Fletcher DC, Schuchard RA. Preferred retinal loci relationship to macular scotomas in a low-vision population. *Ophthalmology* 1997;104:632-638.
  - 13 Schuchard RA, Fletcher DC. Preferred retinal locus. A review with applications in low vision rehabilitation. *Low vision and vision rehabilitation. Ophthalmol Clin North Am* 1994;7:243-256.
  - 14 Whittaker SG, Budd J, Cummings RW. Eccentric fixation with a macular scotoma. *Invest Ophthalmol Visual Sci* 1988;29:268-278.
  - 15 Merchant J, Morrissette R, Porterfield JL. Remote measurement of the eye direction allowing subject motion over an cubic foot of space. *IEEE Trans Biomed Eng* 1978;21:309-317.
  - 16 Fourcy J, Pernier J, Bez M, Jeannerod M. Cyclope. Un capteur de position du globe oculaire non contraignant à base de technique video et microprocesseur. *Innov Tech Biol Med* 1980;1:44-60.
  - 17 Charlier J, Hache J-C. New instrument for monitoring eye fixation and pupil size during the visual field examination. *Med Biol Eng Comput* 1982;20:23-28.
  - 18 Levine JL, Schappert M. Performance of an eye tracker for office use. *Comp Biol Med* 1984;14:77-89.
  - 19 Buquet C, Charlier J. Quantitative assessment of the static properties of the oculo-motor system with the photo-oculographic technique. *Med Biol Eng Comput* 1995;32:197-204.
  - 20 Safran AB, Duret F, Mermoud C, Achard A. A new system for analysing the eye movement strategies in subjects with central scotomas. *J Videol* 1996;1:9-13.
  - 21 Heinen SJ, Skavenski AA. Adaptation of saccades in fixation to bilateral foveal lesions in adult monkey. *Vision Res* 1992;2:365-373.
  - 22 Becker W. Metrics. Reviews of oculomotor research. In: Wurtz RH, Goldberg ME, editors. *The Neurobiology of Saccadic Eye Movements*. Amsterdam, New York, Oxford: Elsevier, 1989; Vol. 3, 13-67.
  - 23 Viviani P, Swensson R. Saccadic eye movements to peripherally discriminated visual targets. *J Exp Psychol Hum Percept Perform* 1982;8:113-126.
  - 24 Meienberg O, Zangmeister WH, Rosenberg M, Hoyt WF, Stark L. Saccadic eye movements strategies in patients with homonymous hemianopia. *Ann Neurol* 1981;9:537-544.
  - 25 Zangmeister WH, Oeschner U. Evidence for scanpaths in hemianopic patients shown through string editing methods. In: Zangmeister WH, Stiehl HS, Freska C, editors. *Visual Attention and Cognition*. Amsterdam: North-Holland/Elsevier Science BV, 1996; 197-221.